

Examples of healing symptoms of various diseases
using Terahertz-Queen (medical enhancement model)

TokyoMirai Co., Ltd.

President

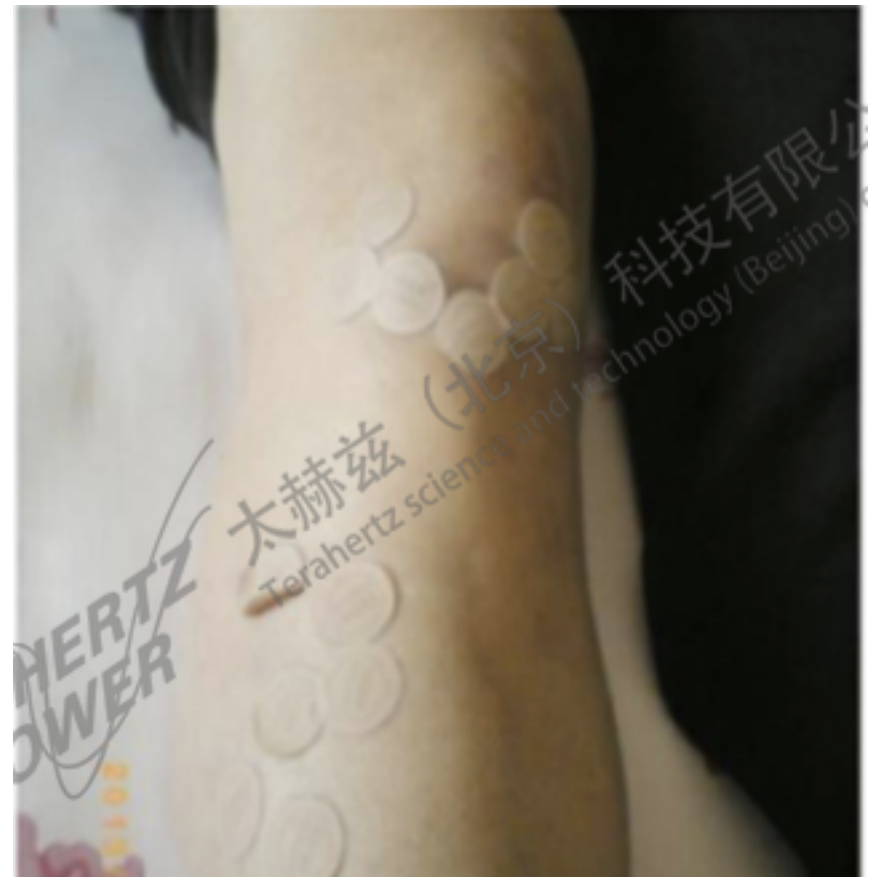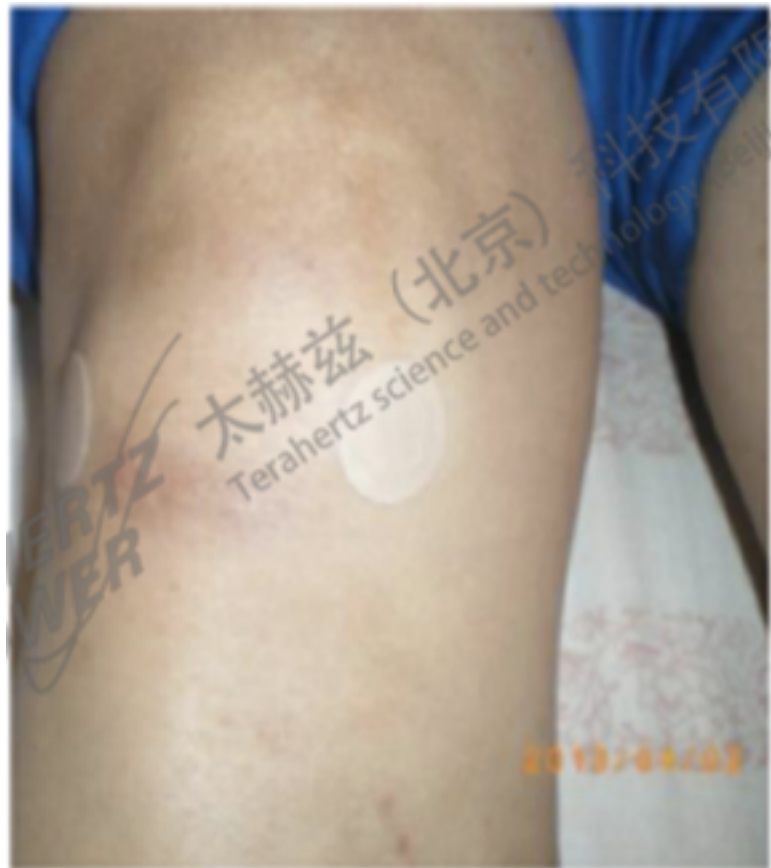Keisuke Uchida

椎間板ヘルニアによるひざ関節肥大

- 1 椎間板ヘルニアと同時にひざ関節肥大を発生、歩行困難状態となった
- 2 THZ治療を2週間継続した結果、関節の腫れは回復し職場への復帰を実現できた

Enlarged knee joint by herniated disc

1. The knee joint enlarged at the same time as the disc hernia, and it became a difficulty walking state
2. As a result of two weeks of continuous thz treatment, the swelling of the joints recovered and returned to work.



肝斑

女兒出產後顏全体に肝斑が発生、レーザー治療を試みるもさらに悪化

THZ治療を5日間継続後、携帯型THZ治療機で自宅で3ヶ月治療を続けた結果完全に回復

Melasma

1. Baby girl after childbirth the whole face is spotted, even worse try laser treatment

2. After five consecutive days of THz treatment, a portable THz treatment machine continued to cure three months at home, resulting in a full recovery

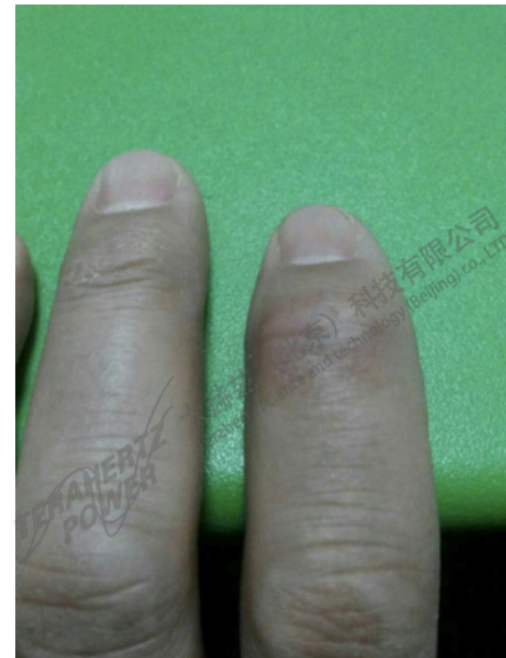
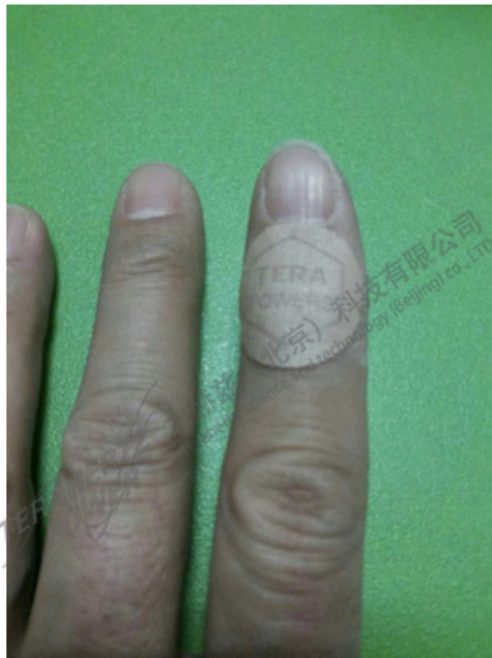
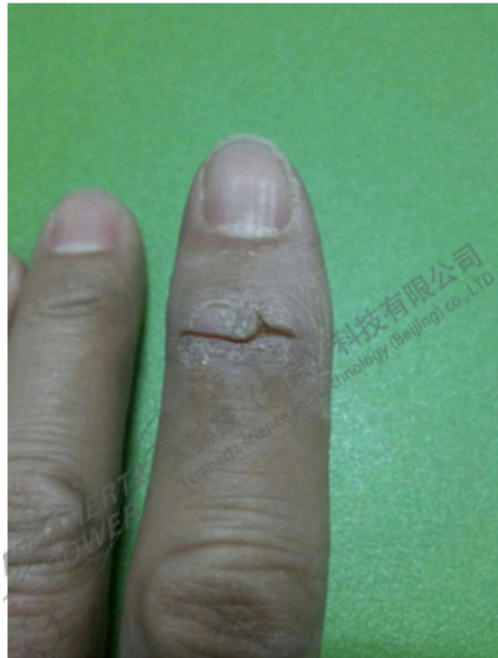手、指のひび割れ

- 1 慢性的に指先にひび割れが発生
- 2 特別な触媒を含有させたパッチにTHz加工を施し、それを貼り付けて治療した(24時間後に完治)

Hand, finger cracking

1. Chronic cracks occur at your fingertips
2. A patch containing a special catalyst with THz processing was pasted into the affected area (cured after 24 hours)

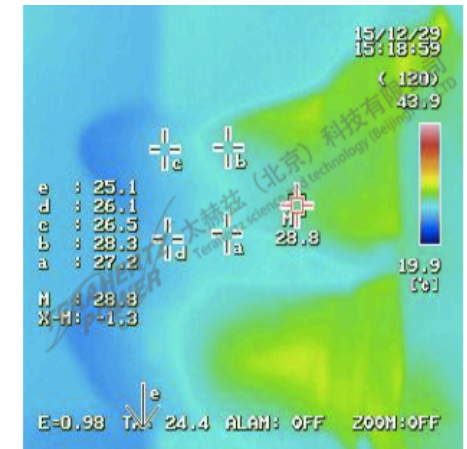

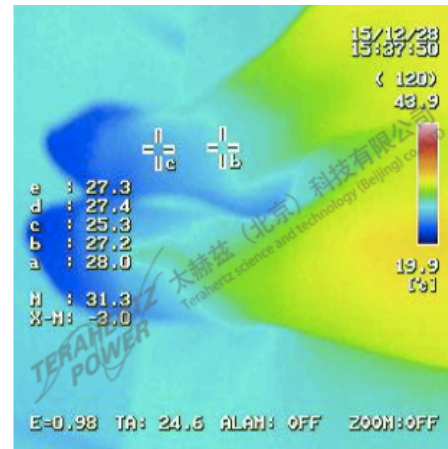
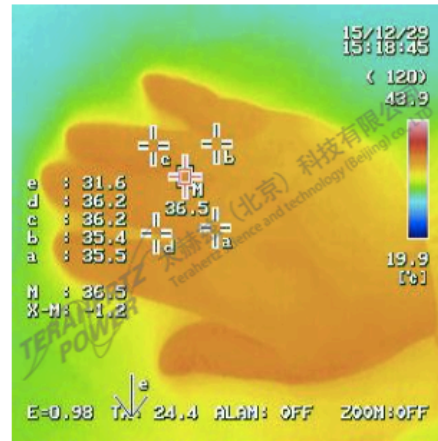
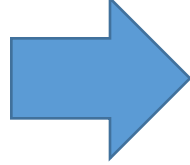
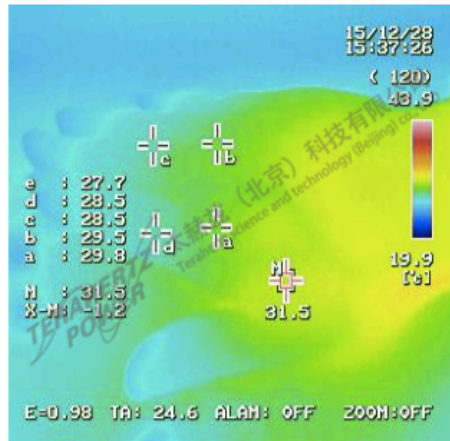


THz照射後の体末端部の温度変化

- 1 通常時の手先・足先の温度分布の状態
- 2 THz照射後、1日経過した各部位の温度上昇の状態

Temperature change at the end of the body after THz irradiation

1. The condition of the temperature distribution of the normal hand and foot
2. Temperature rise in each part of the day after THz irradiation

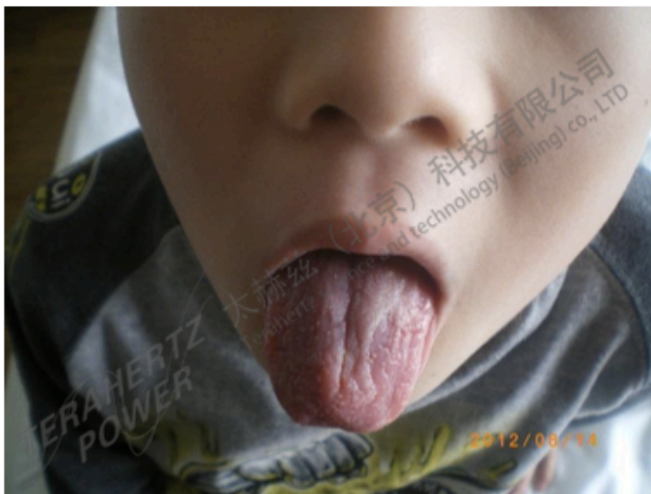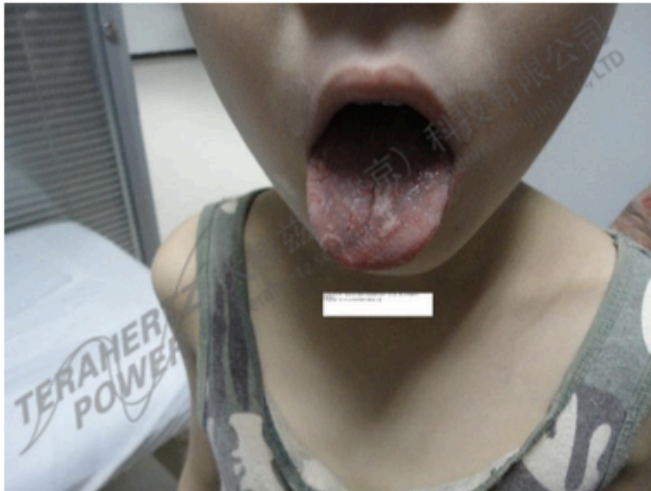


手足口病

1. 病院に長期間通うも改善なし
2. THZ治療を1週間継続した結果ほぼ回復

Limb Mouth Disease

1. No improvement for long-term attendance in hospitals
2. The results of a one-week continuous THz treatment almost recovered

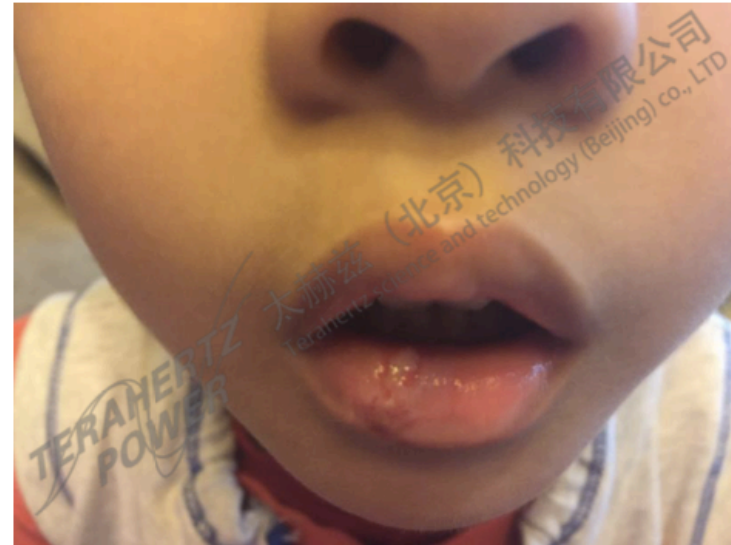
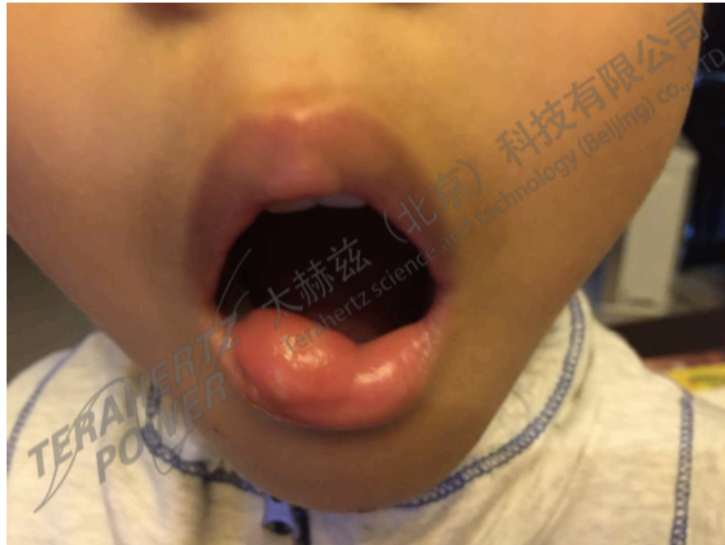
唇の急性炎症

- 1 原因不明の急性炎症を唇部分に発症
- 2 ランダムに複数回THZ治療で照射を行なったところ、24時間後に炎症箇所は回復した

Acute inflammation of the lips

1. Onset of acute inflammation of unexplained causes on the lip part
2. When the irradiation was performed at random multiple times in the THz treatment, the inflammation part recovered after 24 hours.

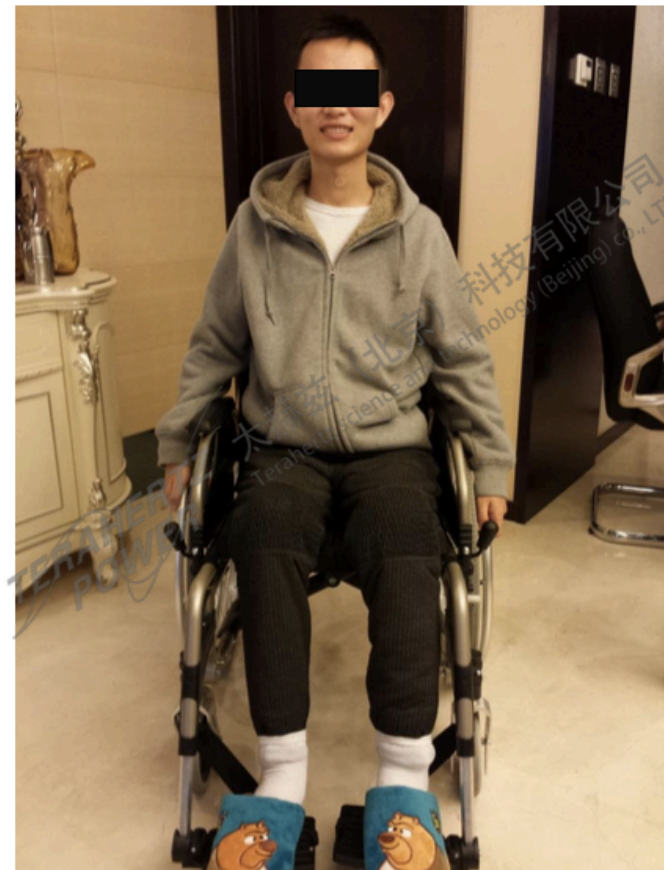
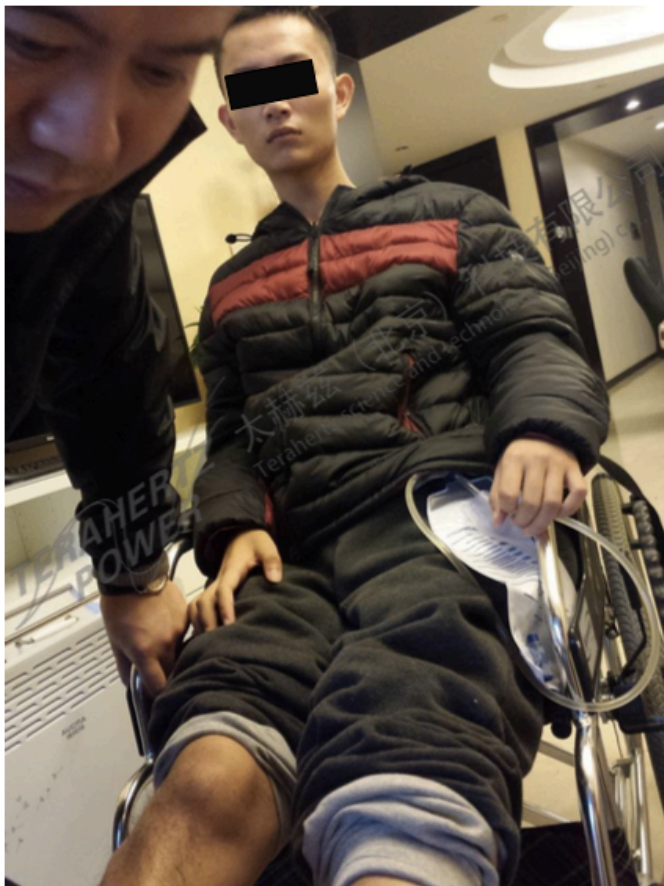
頸椎、腰椎、尾椎による損傷(建物4階からの転落)

- 1 落下事故により脊髄各所に大きな障害を受け歩行不可、精神の状態も悪化し感情がない
- 2 2ヶ月間のTHZ治療の結果、歩行機能を回復し精神、特に健全な感情を取り戻した

Cervical spine and lumbar vertebrae were damaged and the tail vertebra (falling from the building 4f)

1. It became impossible to walk due to the fall accident, and the state of the spirit deteriorated, and feelings were lost.
2. As a result of the two-month THz treatment, recovered the walking function and regained the spirit, especially the healthy feeling



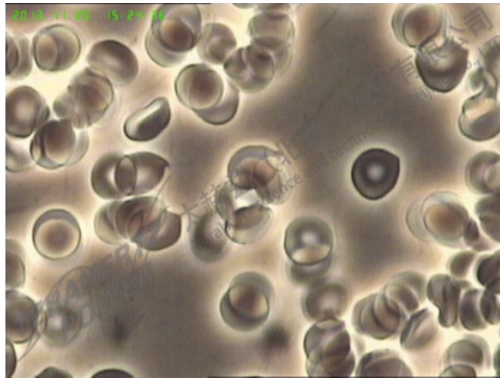
THZ治療30分後の赤血球の変化

- 1 THZ照射前は赤血球粒子が結合し、自由度が大幅に制限された状態となっていた
- 2 通常血液及び乾燥血液の状態を見ても、THZ照射後のフリーラジカルの変化は一目瞭然である

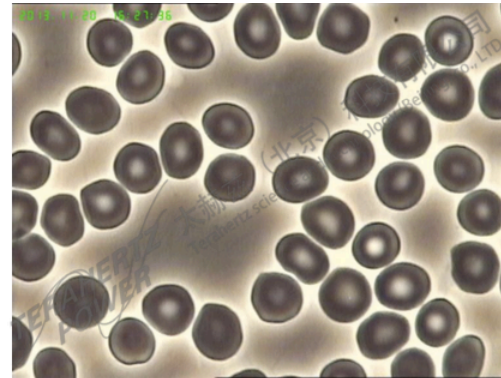
Changes in erythrocytes after 30 minutes of THz treatment

1. Before THz irradiation, the red blood cell particles were bound and the freedom was greatly restricted.
2. The change of free radicals after THz irradiation is obvious even if the condition of blood and dry blood is usually seen.


Before THz treatment



30 minutes after THz irradiation



Changes in normal
blood cells



Changes in dry blood
(erythrocytes)

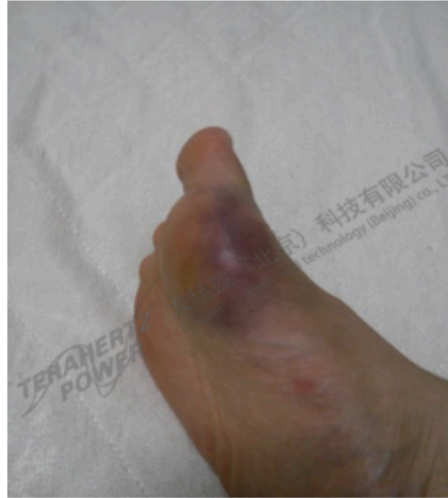足裏部の重度の打撲

- 1 打撲箇所に、5日間に渡りTHZ治療を行なった
- 2 患部の状態はひどかったが、正味4日で元の状態まで回復した

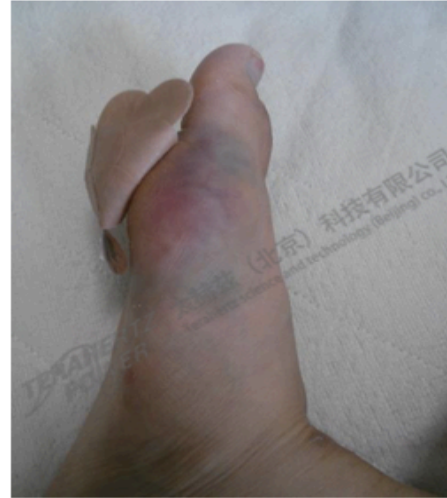Severe bruise on sole

1. The THz treatment continued over five days in the bruised place.
2. The condition of the affected area was terrible, but it recovered to its original state in the net four days.

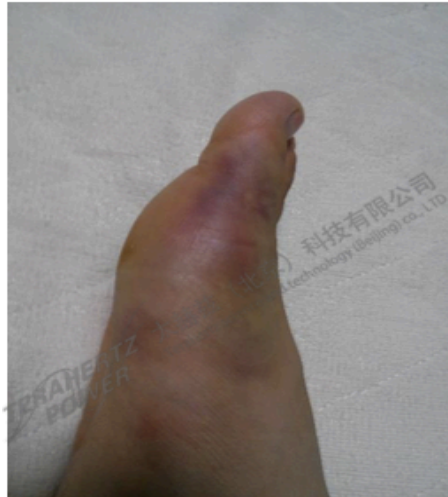Day 1



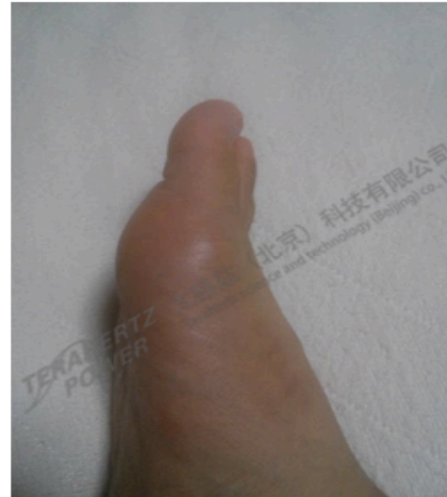Day 2



Day 3



Day 5

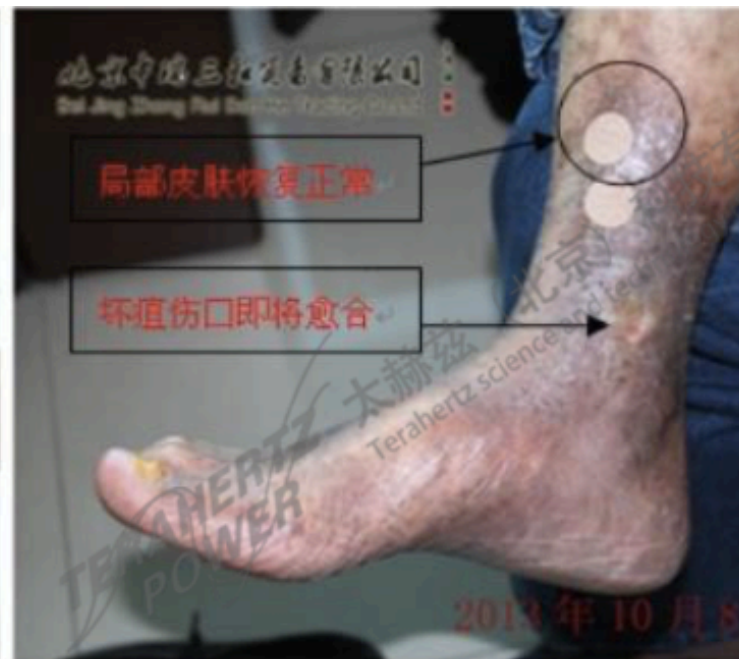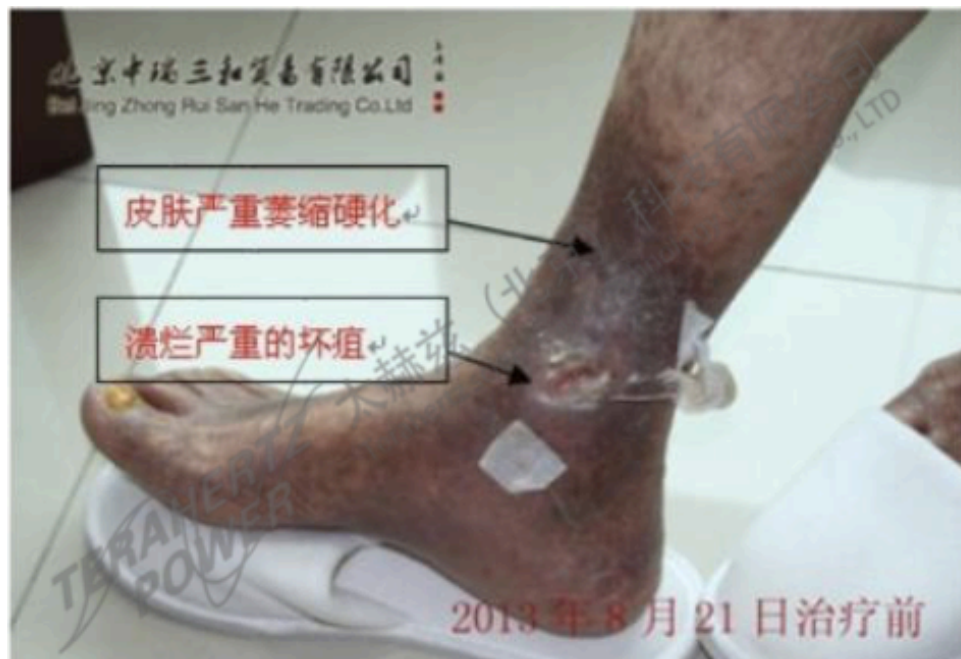


壊疽

- 1 高齢者の重傷静脈炎による壊疽
- 2 THZ治療を5回経て、皮膚表面の状態が大幅に回復した

Gangrene

1. Gangrene by severe venous inflammation in the elderly
2. After five THZ treatments, the skin surface condition recovered significantly.

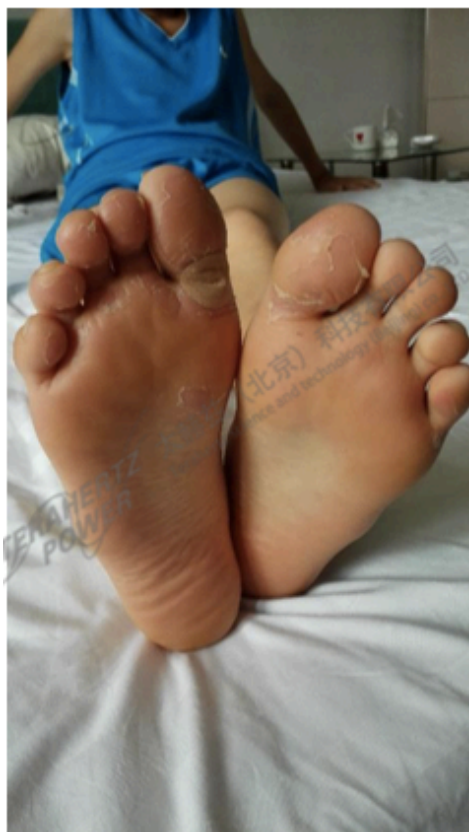

乾癬による重度の足裏のひび割れ

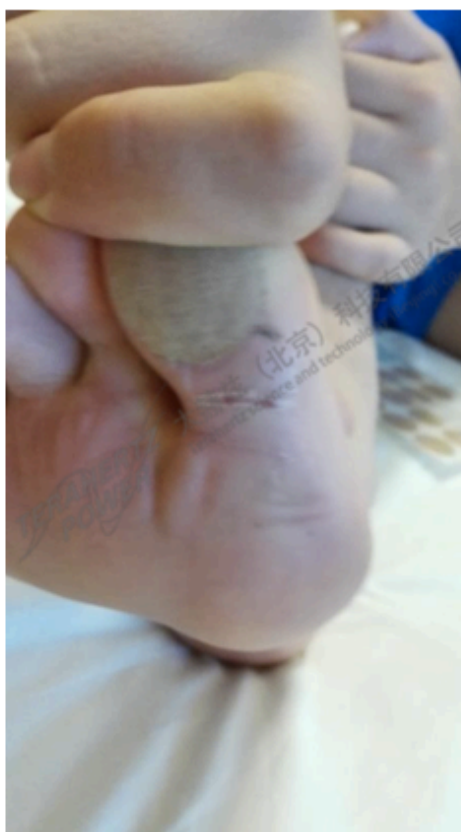- 1 乾癬による重度の足裏のひび割れが発生し、痛みで歩行が困難となった
- 2 THzの治療の結果、翌日には開口部がふさがり、さらに二日後にはその周囲の状態も回復した

Severe foot cracks caused by psoriasis

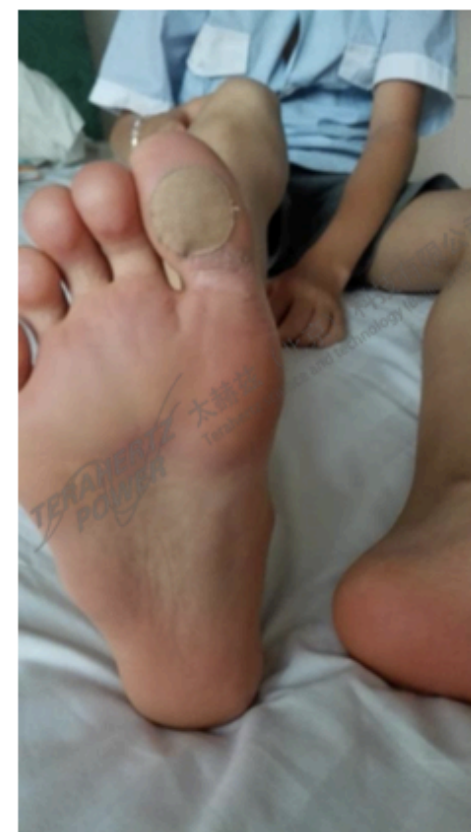1. Severe foot cracks caused by psoriasis made it difficult to walk in pain.
2. As a result of the treatment of THz, the wound which had rotted the next day interposed, and the condition of surroundings also recovered two days later.



DAY 1



DAY 2



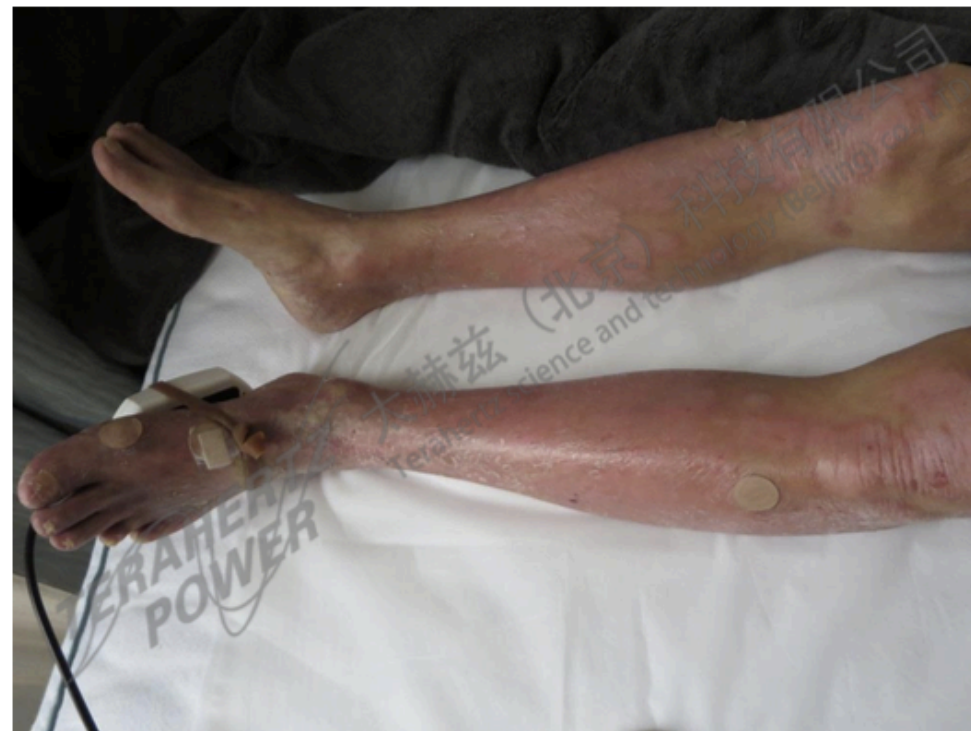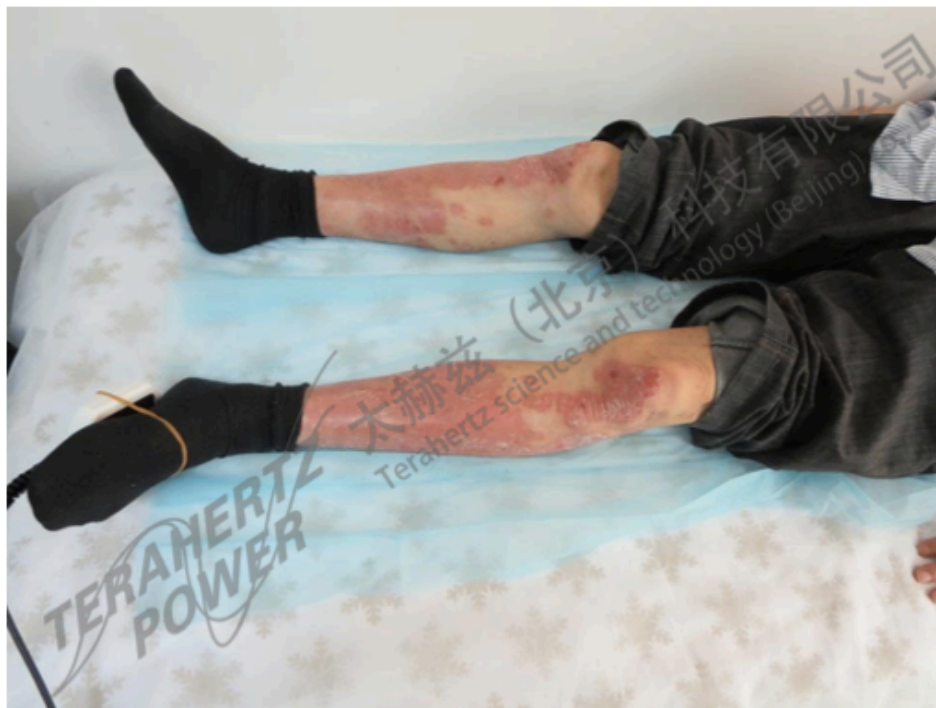DAY 3

糖尿病

- 1 病状が悪化し指先の一部に壊死が始まった(特に左足)
- 2 THz治療機で1ヶ月治療、指の切断は免れ皮膚の状態もほぼ回復した

Diabetes

1. The condition deteriorated and necrosis began on the part of the fingertips (especially left leg)
2. One month treatment in the THz treatment machine, the cutting of the finger escaped, and skin condition almost recovered



湿疹

1. 全身に原因不明の湿疹により強烈な痒みが発生
1. THZ照射装置で2時間治療、痒み状態共に落ち着いた

Eczema

1. Severe itching caused by unexplained eczema in the whole body
2. Two-hour treatment with THz irradiation device, itchy and state of the body settled

